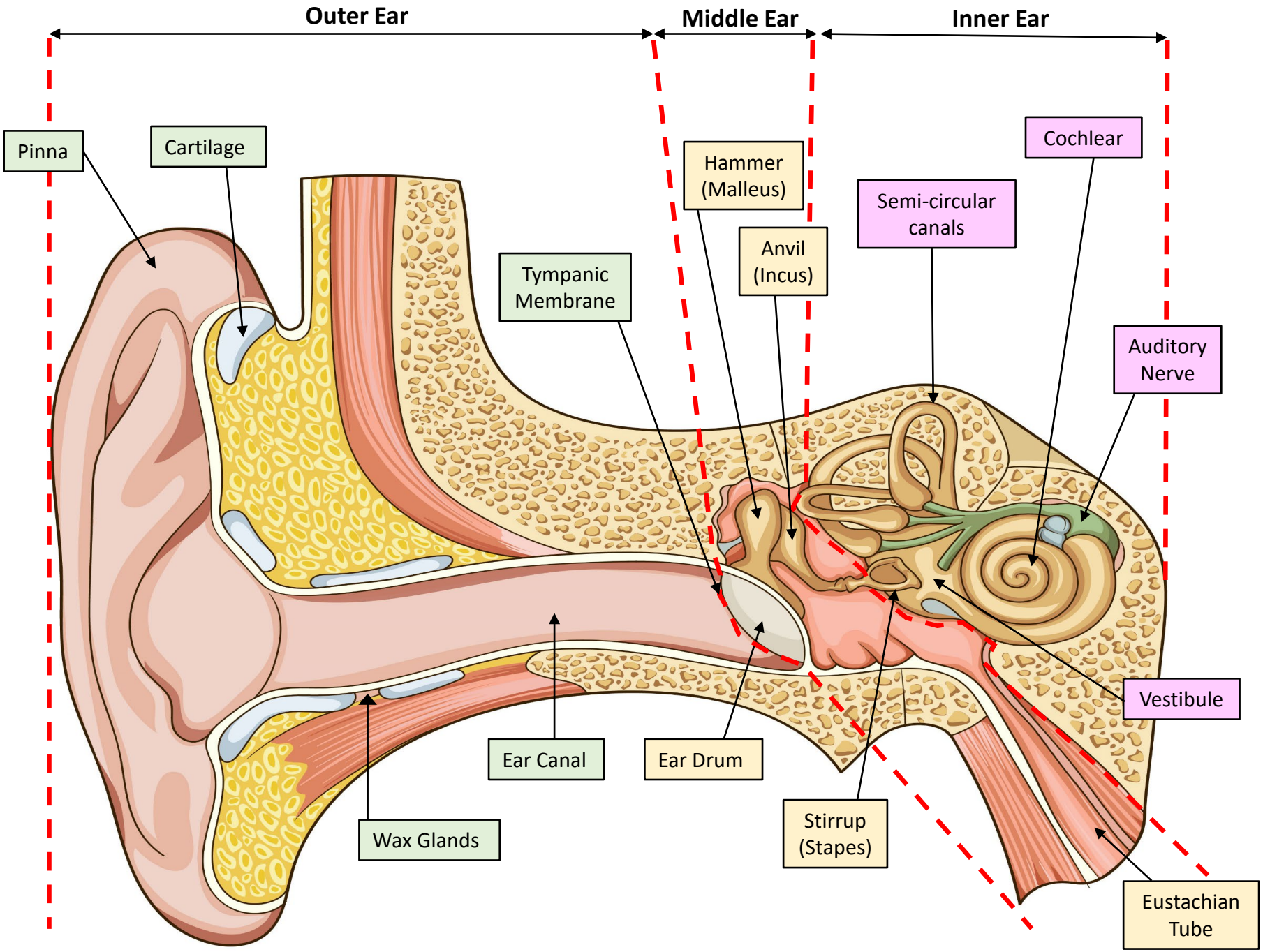
Outer Ear
Middle Ear
Inner Ear
Pinna
Cartilage
Hammer (Malleus)
Cochlear
Semi-circular canals
Anvil (Incus)
Tympanic Membrane
Auditory Nerve
Vestibule
Ear Canal
Ear Drum
Stirrup (Stapes)
Wax Glands
Eustachian Tube